

ORIGINAL ARTICLE

## Use of a TriPollar radio-frequency device for the treatment of acne vulgaris

JONATHAN NEVIN T. YU & PAMELA HUANG

*Skin and Cancer Foundation Inc., Manila, Philippines*

### Abstract

**Introduction:** Acne vulgaris is a common disease affecting mainly teenagers and young adults. Current treatment modalities include local or systemic medications, which often require a long intake. Light and radio-frequency (RF) devices have recently been used to treat acne in selected patients. **Objective:** To evaluate the safety and efficacy of TriPollar RF technology for non-invasive treatment of acne vulgaris lesions. **Methods:** Twenty patients with active acne lesions underwent TriPollar RF treatments once a week for 6 weeks. Results were evaluated using photographs and active lesion counts at baseline, before subsequent treatment sessions and at follow-up visits. Patients also rated their satisfaction on a 5-score rating scale. **Results:** An average reduction of 42% in active acne lesions was found after six TriPollar sessions, which was sustained at the 4-week follow-up visit. The average improvement rated by patients at the 4-week follow-up visit was 2.5, indicating good to very good satisfaction with the clinical results. No significant adverse events were recorded during the study and follow-up period. **Conclusion:** The findings confirm the safety and efficacy of TriPollar RF for the treatment of acne vulgaris.

**Key Words:** *acne vulgaris, Apollo, radio frequency, TriPollar*

### Introduction

Acne vulgaris is a common disease that primarily affects teenagers and young adults, but may also be of concern for some middle-aged individuals. It affects all races and all socioeconomic classes. It has a slight male predominance, probably due to hormonal influence. While some may regard acne as a normal occurrence during puberty, for most patients acne will have a significant impact on their quality of life.

The pathogenesis of acne relies on four main factors: inflammation, follicular dyskeratinization, overactive sebaceous glands, and *Propionibacterium acnes* proliferation. Treatment is directed towards one or several of these factors and can be local or systemic. Local therapies such as topical antibiotics, benzoyl peroxide, azelaic acid, sulfur, resorcinol and retinoids have been used for years. Systemic agents include the antibacterials and those that combat hormones: anti-androgens, contraceptives, and isotretinoin. Most clinicians also advocate the usefulness of acne surgery and intralesional glucocorticoids. Combinations of these may help in achieving the best response possible.

Despite the multitude of choices in the armamentarium against acne, many patients may still remain unsatisfied. Most medications require months of daily application or intake. This affects adherence to regimens and, therefore, compliance to treatment. Therefore, it would be beneficial to investigate newer modalities that can offer comparable or better efficacy in a more convenient way.

In recent years, the use of lasers and different light sources has been under investigation for their possible role in the treatment of acne. Owing to advances in research and an increase in knowledge about the many possible applications of these new technologies, physicians have been encouraged to seek new and exciting possibilities.

Radio frequency (RF), a relatively new technology in skin rejuvenation, allows heating of the dermal tissues with cooling of the epidermis, thus sparing it from damage. This modality is said to also target the sebaceous gland, an important part in the pathogenesis of acne, by causing shrinkage and decreasing sebum output. TriPollar RF is a new RF technology,

based on three or more electrodes. One electrode acts as a positive pole while the other two act as negative poles. The current flowing through the common, positive pole is twice that which flows through each of the negative poles. To avoid overheating of this common pole and of the tissue in contact with this pole, a sequence of electrical modulation is applied so that each electrode, in turn, acts as the common pole. Owing to this design, no active cooling of the electrodes or the skin is required.

### Materials and methods

The Apollo™ system (Pollogen Ltd.) delivers RF current at a frequency of 1 MHz and a maximum power of 50 watts. The system consists of a main unit, three applicators, foot switch and a bio-feedback control. The three applicators differ in size and configuration and are indicated for treatment of various body and facial areas. Applicator no. 1 is indicated for the treatment of large body areas, applicator no. 2 is indicated for the treatment of medium-sized body areas and various facial areas, and applicator no. 3 is indicated for the treatment of very small facial areas such as around the upper lip, below the eye and above the eye in the brow bone area. The operator can adjust treatment parameters such as power level and treatment time. No active cooling of the electrodes or the skin is required.

Twenty patients (five males and 15 females) were recruited for this study and were evaluated at a private dermatology clinic in Manila, Philippines. Their ages ranged from 18 to 36 years (average 24.2 years). Patients had active acne lesions defined as: erythematous papules, pustules and inflamed cysts. Those included in the study were not satisfied with their current treatments and had been off topical or oral medications for at least 2 months. The patients were

all willing to try this new treatment modality for their acne. Exclusion criteria included pregnancy, any pacemaker or implanted electronic device that could be affected by the RF energy, and any active dermatological or collagen-vascular disorder. Patients were assessed medically and signed an informed consent form before the start of the study.

Each patient underwent six sessions of TriPollar RF treatment once weekly. Prior to the start of each session, glycerin was applied to the treatment area and was thoroughly washed off after the session ended. The procedure took about 15 minutes to complete using applicator 2 at a power of 12.5 watts, with emphasis on problematic acne areas. Skin temperature was monitored using an infrared thermometer and, according to the protocol, must reach 41°C and be maintained for at least 2 minutes.

During the entire duration of the study, the patients were not allowed to apply or take any acne medications, nor were they allowed to undergo any other physical treatment. Patients had their photographs as well as their active lesion counts taken at baseline, before each of the subsequent treatment sessions and at follow-up visits at 1 week, 2 weeks and 4 weeks after the last treatment. Photographs were taken in a standardized fashion using a 10.1 mega pixel camera (Sony DSC-N2). Photographs were assessed by the investigator and one other dermatologist who was not an investigator in this study.

After completing their six treatments, the patients answered a questionnaire rating their acne improvement at follow-up visits. A 5-score rating scale was used to rate satisfaction: 0 = none, 1 = mild improvement, 2 = good, 3 = very good, 4 = excellent.

Subjects enrolled in the study were free to discontinue their participation at any time. A decision to discontinue participation did not prejudice their

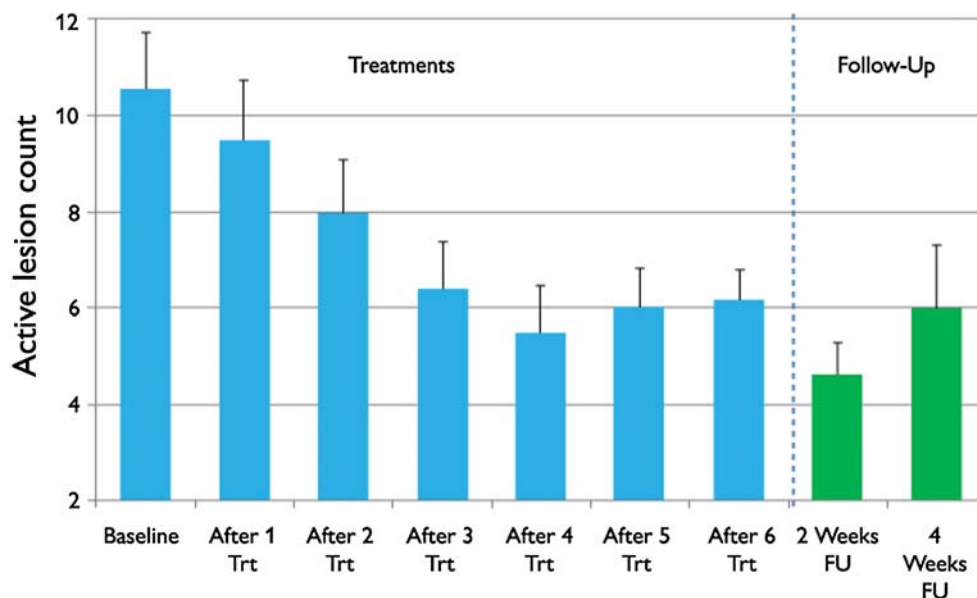


Figure 1. Average reduction in active acne lesions following TriPollar treatments.

medical care. In those instances, investigators attempted to obtain clinical results concerning the subject prior to withdrawal.

Patients were also followed for any adverse events occurring throughout the study period.

Active acne lesions were counted at baseline, before each successive treatment and at the follow-up visits. Mean values were calculated from raw data and differences between baseline and follow-up measurements were analyzed using paired Student's *t*-test at a significance level of  $p < 0.05$ .

## Results

Twenty patients were enrolled in the study and 13 completed it (of the withdrawals, four patients completed four treatments while three completed two treatments). The patients who withdrew during the study did so for personal and not treatment-related reasons. Figure 1 shows a histogram representing an average reduction of 42% in active acne lesions in the 13 patients who completed the six weekly treatments. This reduction was statistically significant ( $p = 0.003$ ), with the average reduction sustained at 43% at the 4-week follow-up. Figure 2 shows a 27-year-old female with six active lesions on the left side, which decreased to one after six treatments and was sustained until after 4 weeks following her last TriPollar RF treatment.

No significant adverse events were recorded during the study and follow-up period. Average improvement as rated by patients at the 4-week follow-up visit was 2.5 on the rating scale, indicating good to very good satisfaction with the clinical results.

## Discussion

Acne vulgaris therapy can still benefit from non-traditional forms of treatment. There will be a subset of patients who will not respond to traditional therapies nor be willing to topically or systemically medicate themselves for their acne. To this end, multiple light and heat energy systems have been investigated and introduced for clinical use over the past few years. Some light-based systems, mostly those centered around the blue light wavelengths, target *P. acnes* through a photo-chemical process; however, others, as well as RF and hot plate devices, rely on heat to different skin depths to affect the sebaceous glands. Paithankar et al. (1) examined the use of a 1450 nm, mid-infrared, diode laser for thermolysis of sebocytes (and their resident *P. acnes*). They observed marked decreases in the number of inflammatory lesions 12 weeks after weekly treatments for 1 month. In a later human split-face study they found a 47% reduction in acne lesions on the treated side and 18% on the control side at 1 month after the final treatment. Ross (2) notes that maximum heating with this laser and epidermal cooling is about 300–400 microns whereas most *P. acnes* and enlarged sebaceous glands lie deeper in the dermis, and speculates that this laser might work through direct heating of the infundibulum, hence improving sebum outflow and 'resetting' the keratinization pattern in the follicle. Since it is likely that heat produced by RF will have a deeper effect on the sebaceous glands, Ruiz-Esparza and Gomez (3) used the ThermoCool™ device (Thermage Inc., Hayward, CA, USA) and observed an excellent response in 18 of 22 patients (82%) and a modest response in 9%. Furthermore, the authors noted clinical improvement in

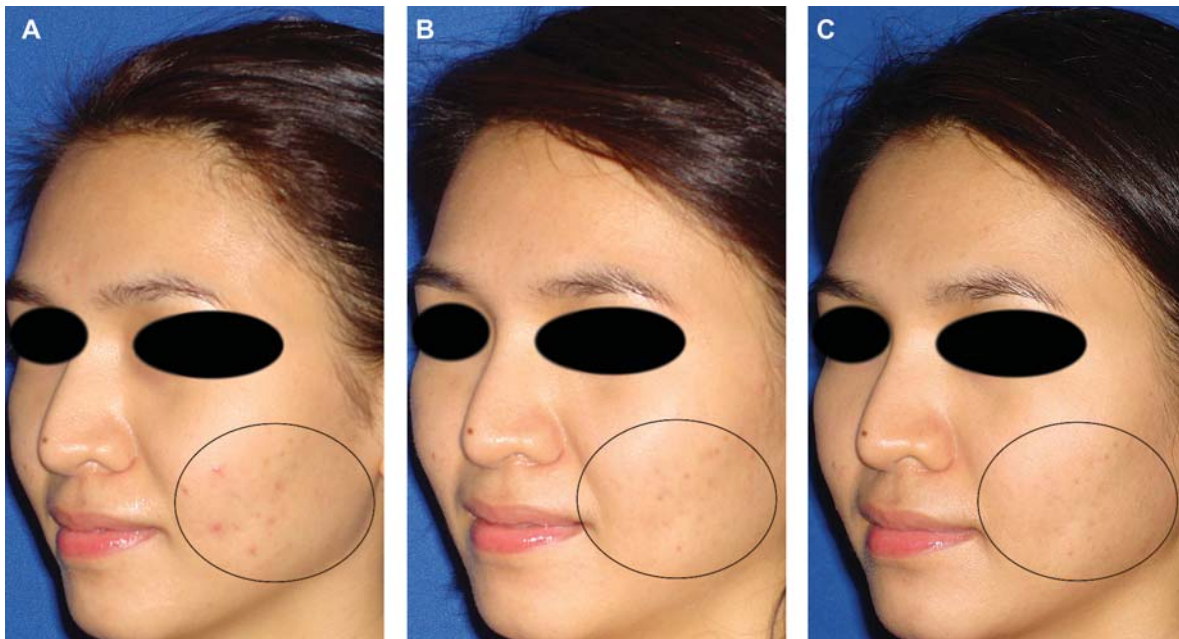


Figure 2. A 27-year-old female showing a decrease in active acne lesions.

acne scarring, which is not surprising since these same devices have been studied and are clinically approved for facial skin tightening and wrinkle removal, based on dermal collagen shrinkage and collagen remodeling. Acne thermolysis with the 1450 nm laser has since been further studied but its exact mechanism of action is still not clear (4) and widespread clinical use is limited due to significant pain associated with this particular modality (5). Finally, at least two heat-based, home use devices have recently been cleared for marketing by the FDA. These devices (Zeno™; Zeno Corp., Houston, TX, USA and ThermaClear™; Therative, Livermore, CA, USA) use small, heated metal plates to treat individual acne lesions as they develop. Preclinical experiments conducted on the Zeno device showed that the amount of heat required to reduce colony counts from treated anaerobic cultures of *P. acnes* was tolerable to human skin. Clinical trials with both devices showed that low-level heat in the range of 40°C is effective in reducing time to improvement and time to resolution of acne lesions (6).

The Tripollar RF device used in this study has previously been shown to be effective for skin tightening and body shaping (7–9), based on creating deep dermal heat without pain or any serious adverse effects. Patients undergoing the Tripollar RF treatments for acne tolerated the procedure well with no topical anesthesia and no down time. The treatment may work by heating of the sebaceous glands, which leads to increased metabolism and shrinkage of the gland, therefore decreasing sebum production and leading to a decrease in *P. acnes*. Additionally, increased blood circulation by the thermal effect of RF may increase available oxygen, which may also favorably affect *P. acnes* bacteria. It is also postulated (10) that the pilosebaceous unit has a higher electrical resistance as compared to surrounding skin leading to faster, selective heating of the follicle and gland while leaving surrounding dermal and epidermal tissues intact.

## Conclusion

Tripollar RF treatment offers a painless, quick and convenient treatment method to decrease active acne lesions, improve patients' skin appearance, reduce

anxiety related to acne and its treatment, and avoid the development of acne scars. Based on previous studies using RF for skin rejuvenation, this technique may also be potentially effective for the decrease in the appearance of acne scars. This modality is particularly useful for patients who are not willing or capable of adhering to a daily regimen and for those who have failed medical management. There are also patients who prefer to avoid long-term drug treatment owing to concerns or experience with the significant side effects associated with isotretinoin and other medications.

**Declaration of interest:** The authors report no conflicts of interest. The authors alone are responsible for the content of the paper.

## References

1. Paithankar DY, Ross EV, Saleh BA, Blair MA, Graham BS. Acne treatment with a 1,450 nm wavelength laser and cryogen spray cooling. *Lasers Surg Med.* 2002;31(2):106–14.
2. Ross EV. Optical treatments for acne. *Dermatol Ther.* 2005;18(3):253–66.
3. Ruiz-Esparza J, Gomez JB. Nonablative radiofrequency for active acne vulgaris: The use of deep dermal heat in the treatment of moderate to severe active acne vulgaris (thermotherapy): A report of 22 patients. *Dermatol Surg.* 2003;29(4):333–9; discussion 339.
4. Laubach HJ, Astner S, Watanabe K, Clifford J, Rius-Diaz F, Zurakowski D, et al. Effects of a 1,450 nm diode laser on facial sebum excretion. *Lasers Surg Med.* 2009;41(2):110–5.
5. Bernstein EF. Double-pass, low-fluence laser treatment using a large spot-size 1,450 nm laser improves acne. *Lasers Surg Med.* 2009;41(2):116–21.
6. Gold MH, Sadick NS, Bradshaw VL, Boring MM. A randomized, controlled, double-blind study of localized low-heat treatment of acne lesions. *Cosmet Dermatol.* 2007;20(8):495–9.
7. Kaplan H, Gat A. Clinical and histopathological results following TriPollar radiofrequency skin treatments. *J Cosmet Laser Ther.* 2009;11(2):78–84.
8. Boisnic S, Branchet MC. Ex vivo human skin evaluation of localized fat reduction and anti-aging effect by TriPollar radio frequency treatments. *J Cosmet Laser Ther.* 2010;12(1):25–31.
9. Levenberg A. Clinical experience with a TriPollar™ radiofrequency system for facial and body aesthetic treatments. *Eur J Dermatol.* 2010;20(5):1–5.
10. Sadick NS, Shaoul J. Hair removal using a combination of conducted radiofrequency and optical energies—An 18-month follow-up. *J Cosmet Laser Ther.* 2004;6:21–6.