

One Clinic's Experience in the Treatment of Varicose Veins and Leg Telangiectasias with the VascuLight™ Intense Pulsed Light / Nd:YAG Laser Source

Marc Troxler, MD (Phlebologist), Venezentrum, Arlesheim, Switzerland

INTRODUCTION

Lasers have been used with varying degrees of success over the past two decades to treat a number of vascular lesions. Problematic leg vessels constitute an integral part of the number of patients suffering from vascular indications. A number of options such as lasers, intense pulsed light (IPL™) therapy, and sclerotherapy are available for the treatment of small and superficial vessels, while deeper or larger diameter veins, particularly those with underlying vascular disease, are commonly treated by surgical intervention with ligation and stripping.¹⁻⁷

During the past five years, I have used an IPL source for the treatment of vascular conditions such as adult port wine stains, facial and truncal telangiectasias, and hemangiomas. With the addition in 1998 of the VascuLight system to my clinic, I have been able to take a bimodal approach (IPL and Nd:YAG laser therapy) to expand the treatment of leg vessels to include varicose veins up to five mm in diameter.

In the treatment of over 9,000 patients in my clinic, my three colleagues and I have observed that the incidence of well known side effects, which occur with sclerotherapy such as matting, hyperpigmentation and skin necrosis, are rare with VascuLight

IPL/Laser treatment. Furthermore, the system can be used to treat various types of pigmented lesions, including discoloration such as hyper-pigmentation and hemosiderin stains, which often develop as a result of sclerotherapy. We have been able to achieve a high degree of success and patient satisfaction in treating various vascular lesions and pigmented lesions with the VascuLight device.

METHOD

VascuLight IPL / Laser System

The VascuLight system consists of an IPL source and a laser source. The IPL source operates with a broad wavelength spectrum from 515 to 1200 nm and a fluence range of 3 to 90 J/cm². The laser source consists of a 1064 nm Nd:YAG laser with high energy fluences up to 150 J/cm². A range of wavelengths and high energy, as well as a multiple synchronized pulsing option (single, double and triple pulses) with long pulse capability (2-16 msec) provide differential heating and cooling of the various sized vessels, located at different depths. Thereby, a range of vessel sizes and skin types can be safely and effectively treated.⁸⁻¹⁰

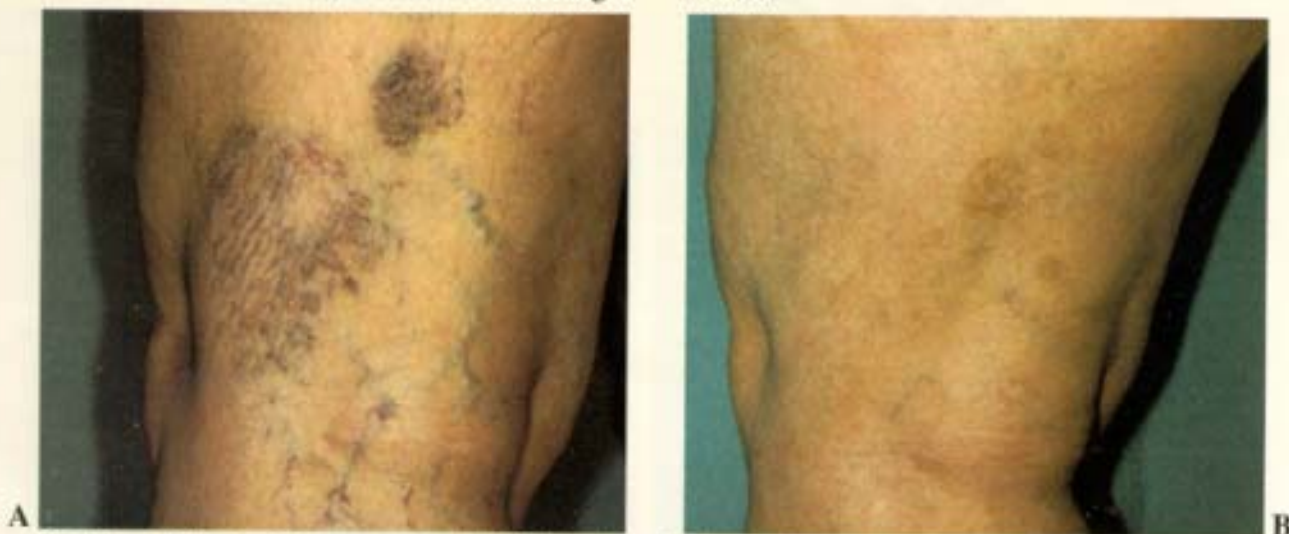


Fig. 1: A combination of 5 treatments; 2 with Nd:YAG and 3 with IPL. The 2 treatments with the Nd:YAG laser were at 140 J/cm², double pulse of 5/5, delay of 15ms. The 3 IPL treatments were at 47 J/cm², double pulse of 4.5/4.5, delay of 15ms. Treatments were given within a 5 day period of time. **Photo A:** before treatment. **Photo B:** 3 months after last treatment.

Treatment Procedure

We have achieved successful clearance of problematic leg vessels, in thousands of patients, by utilizing several treatment approaches. A detailed description of this treatment regime, which occurs in an outpatient setting over one to four days, is as follows:

Step 1. Patient Evaluation

1. A pre-treatment diagnostic work-up, involving a thorough clinical examination performed with duplex ultrasound.
2. Photographic documentation of the problematic area.
3. Decision of treatment plan.

Step 2. Surgical Intervention - Day 1

1. Using local anesthesia, ligation and stripping of the veins are performed where indicated - for incompetent long or short saphenous veins or incompetent perforators.
2. Large feeder veins and branches over 6 mm in diameter are removed by hook phlebectomy.

Step 3. Sclerotherapy and/or VascuLight Treatment - Days 2 to 4

1. In the absence of pathology or following surgical intervention, VascuLight treatment and/or sclerotherapy is performed. Multiple treatments over the next three consecutive days are administered where indicated. This allows us to monitor the effects of the treatment and adjust the parameters as needed. Sclerotherapy and VascuLight treatment have been administered on the same day without adverse effects.

2. VascuLight therapy allows flexible treatment - parameters can be changed to produce improved results. We typically use the following parameters as a baseline and adjust accordingly, where required:

- a. Smaller veins from 1 to 2 mm and skin types I and II are treated with the IPL mode: 570 or 590 nm cut-off filters, double pulses of 3-5 msec/15 msec delay and high fluences of 45-50 J/cm². Thick layers of cold gel (5-10mm) are used in conjunction with these parameters.
- b. Larger veins from 3 to 5 mm or darker skin types are treated with the Nd:YAG laser mode: double pulses of 3-7 msec/15 msec delay and fluences of 140-145 J/cm² (applied directly to the skin with the "V technique").

V technique: The hand piece is directed to the skin at a 45° angle on both sides of, and perpendicular to the vessel, thereby delivering two pulses to the vessel without overlap and thus, producing more effective closure from both sides, without damaging the epidermis. Several passes along the vessel, at a distance of 5-10mm between passes, are usually necessary until the vessel is closed (no emptying of the vessel by finger compression is observed). See diagram - Application 1.

- c. The Nd:YAG laser mode is also used for smaller telangiectasias (1-2mm) for skin types III or darker or where IPL treatment is contraindicated.

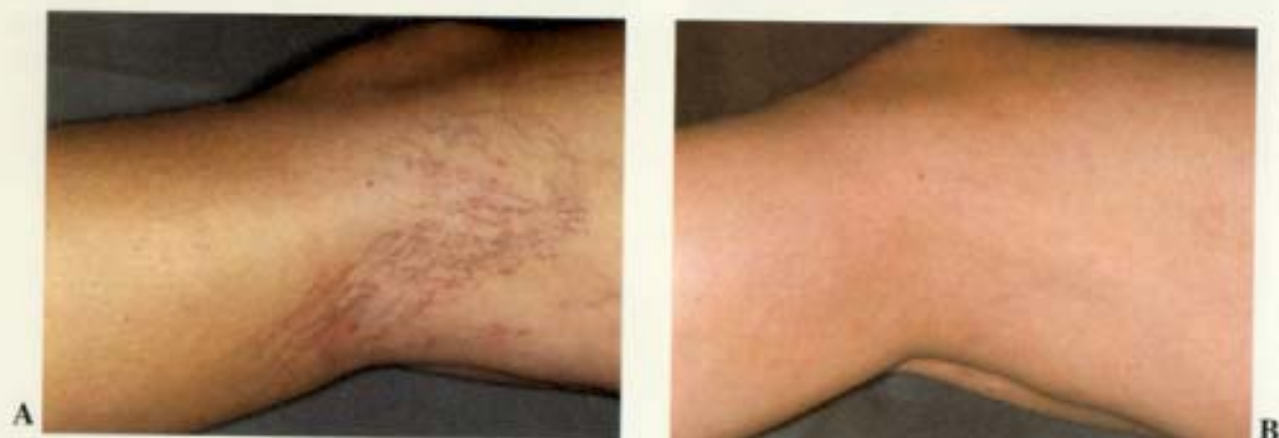

Fig. 2: 4 treatments with IPL; 3 treatments were at 45-48 J/cm², double pulse, 3.5/3.5ms, 15ms delay, 570nm filter. The 4th treatment was given after 1 month at 49 J/cm², double pulse, 3.5/3.5ms, 15ms delay, 590nm filter. **Photo A:** before treatment. **Photo B:** 2 months after last treatment.

The laser head is applied to the skin surface or at a distance of 2-5 mm tangential to the vessel, as if we want to "inject" the light into the vessel. Repeated shots (double mode and high fluences of 130-150 J/cm²) are often necessary (see diagram - Application II).

- d. Nd:YAG treatment and IPL treatment are often performed concurrently, without adverse effects, on days 2 to 4. The Nd:YAG laser is applied first, followed by IPL treatment; thereby, resulting in a more effective treatment.
- e. If treatment consists of only VascuLight therapy, without surgical or sclerotherapy, then compression therapy is not needed.

Step 4. Clinical Assessment of Treatment

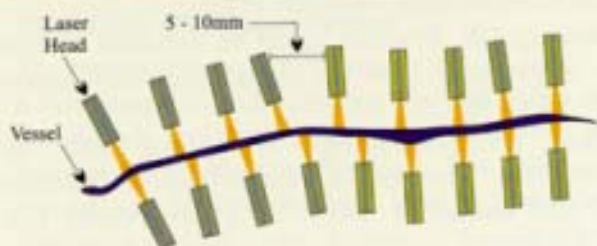
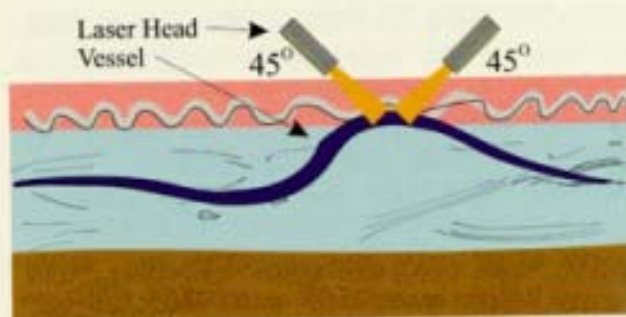
1. Vessel clearance is assessed at 8 weeks after treatment.
2. The degree to which vessels are present on the skin is observed visually and documented with post-treatment photographs.
3. Duplex ultrasound confirms vessel closure.

SUMMARY

VascuLight treatment has been successfully used in our clinic over the past few years to treat thousands of patients. Thousands of cutaneous vascular lesions have been effectively treated with very rare and transient incidents of blisters, erythema or pigmentation. The multi-treatment approach described here has resulted in excellent cosmetic results, very few

complications, and a high level of patient satisfaction. Moreover, patients often prefer the absence of compression therapy, lower rate of side effects, and shorter healing time associated with VascuLight therapy.

V-Technique (Application I) Vessel Diameter: 3-5mm



Tangential Technique (Application II) Vessel Diameter: 1-2mm

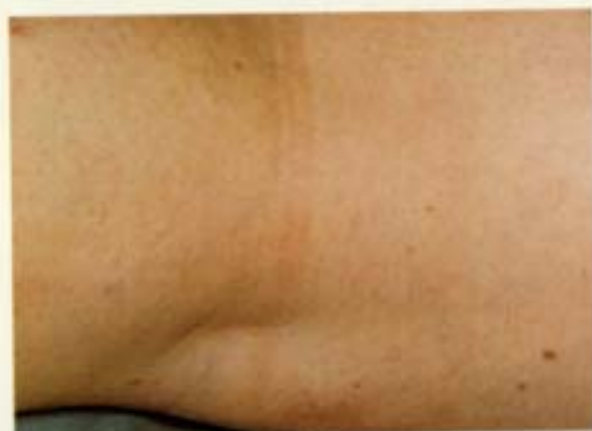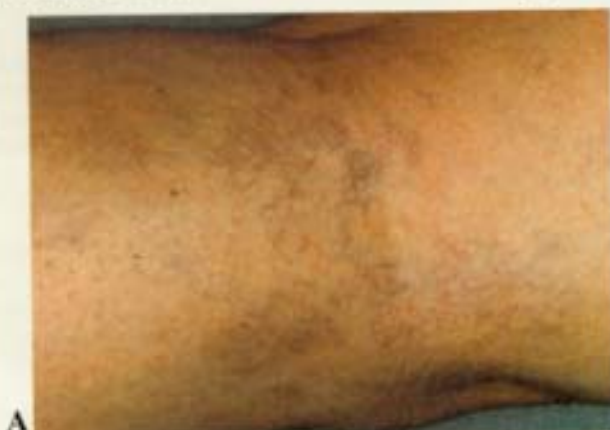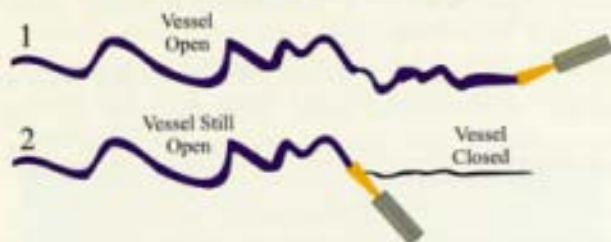


Fig. 3: Fine matting in the fossa poplitea which occurred following sclerotherapy. **Photo A:** before treatment. **Photo B:** 3 1/2 months after 4th IPL treatment.

REFERENCES

1. Goldman MP, Fitzpatrick R (eds). *Cutaneous Laser Surgery. The Art and Science of Selective Photothermolysis*. St. Louis: Mosby-Year Book, 1994.
2. Goldman MP, Eckhouse S. Photothermal sclerosis of leg veins. *Dermatol Surg* 1996; 22:323-330.
3. Garden JM, Bakus AD. Clinical efficacy of the pulsed dye laser in the treatment of vascular lesions. *J Dermatol Surg Oncol* 1993; 19:321-6.
4. Schroeter CA, Neumann HAM. An intense light source: The Photoderm VL-flashlamp as a new possibility for vascular skin lesions. *Dermatol Surg* 1998; 24:743-48.
5. Dixon JA, Heuther S, Rotering R. Hypertrophic scarring in argon laser treatment of port wine stains. *Plast Reconstr Surg* 1984; 73: 771-7.
6. Apfelberg DB. Progress report on extended clinical use of the argon laser for cutaneous lesions. *Lasers Surg Med* 1980; 1: 71-83.
7. Fronek, HS. Sclerotherapy of reticular veins. In: *Ambulatory Treatment of Venous Disease*. Goldman MP and Bergan JJ (eds.). St. Louis: Mosby-Year Book, 1996.
8. Raulin C, Schroeter CA, Weiss RA, Keiner M, Werner S. Treatment of port-wine stains with a noncoherent pulsed light source: a retrospective study. *Arch Dermatol* 1999;135(6):679-83.
9. Weiss RA, Weiss MA. Early clinical results with a multiple synchronized pulse 1064 nm laser for leg telangiectasias and reticular veins. *Dermatol Surg* 1999; 25:399-402.
10. Colaiuda S, Colaiuda F, Gasparotti M. Treatment of deep underlying reticular veins by Nd:YAG laser and IPL source. *Minerva Cardioangiol* 2000; 8: 1-4 (English translation), 4-6 (Italian translation).



ESC Sharplan Headquarters - Corporate

ESC Medical Systems, Ltd.
Yokneam Industrial Park
P.O.B. 240
Yokneam 20692, ISRAEL
Tel 972.4.959.9000
Fax 972.4.959.9050

ESC Sharplan Headquarters - The Americas

ESC Medical Systems, Inc.
100 Morse Street
Norwood, MA 02062 USA
Tel 781.278.7600
Tel 800.562.5916
Fax 781.278.7700

ESC Sharplan Headquarters - Europe

ESC Medizintechnik Vertriebs GmbH
Leonardsweg 2
D-82008 Unterhaching b. Munich GERMANY
Tel 49.89.615.350
Fax 49.89.615.35155

ESC Sharplan Headquarters - Asia

ESC Japan Ltd.
2nd Floor, No. 31 Kowa Building
19-1, Shirokanedai 3-Chome
Minato-ku, Tokyo JAPAN
Tel 81.3.5447.1677
Fax 81.3.5447.1680

Websites

www.escomed.com
www.skinandhealth.com